

## Hoof Care

Horses that are housed in stall or small pens should have their feet picked out daily. This will aid in examination for rocks, sticks or other foreign objects. The removal of mud and organic matter will also reduce the risk for infection or “thrush.” **Thrush** is a foul-smelling bacterial infection that may soften the foot, and in severe cases, invade deeper tissues.

Your horse should be trained to readily pick up its foot when asked. Using a hoof pick, clean the foot from toe to heel, being sure to clean the commisures or sulci on each side of the frog, and sulcus of the frog itself. It is a good idea to clean out the feet after you ride. Carry a hoof pick with you on trail rides, so that you can readily remove rocks or stick from your horse’s hoof.

Extremely dry or brittle feet may cause excessive chipping of the hoof wall. There are several commercial hoof dressings on the market that may be useful. Oral hoof supplements, usually containing biotin and methionine, may aid in hoof growth. Very soft soles may be tender and cause the horse to be lame when walked over gravel. Topical dressings, such as Keratex, iodine, or Venice Turpentine, may be useful in toughening the sole. Talk to us for product recommendations.

### ***Trimming and Shoeing***

Generally, horses are trimmed and/or shod in a 6-week cycle. This guideline may vary due to individual hoof growth differences. It is important to train your horse to stand obediently for the farrier. It is not the farrier’s job to train your horse, and unruly horses can cause injury to the farrier. Training to accept the feet being picked up, and handling by the farrier should begin at birth (imprinting).

The goal of foot trimming is to maintain proper shape and length of the foot. The farrier will usually trim the hoof wall with nippers to remove excess length. The foot is then made level with a rasp. The rasp is then used to shape the foot, and smooth rough edges on the wall.

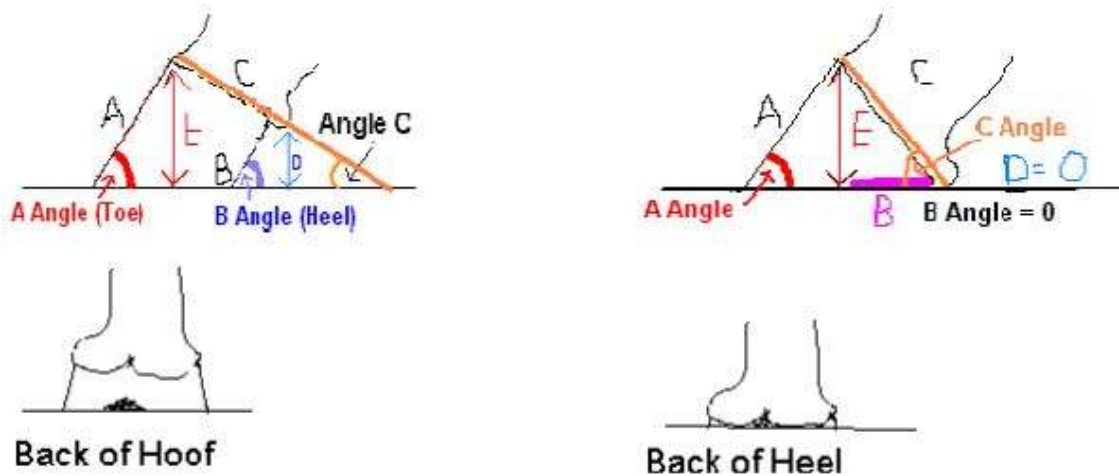
Horses are often shod, but many do not need to wear shoes, and can benefit from routine trimming only. Reasons to show a horse include a need for:

- Traction
- Protection
- Correction

Horses not needing these features may do very well barefoot. The angle of the horse's hoof (when viewed from the side) should be approximately equal to the angle of the pastern. This angle is often very similar to the angle of the shoulder. Horses may have subtle or major differences between left and right. In general, it is desirable to have the feet as equal as possible in shape and angle.

The "ideal" angle for your horse's foot will depend on its conformation. In general, the angle should be between 48° and 55°. The hind feet are typically a little steeper than the forefeet. When the horse is shod, the shoe should be of adequate size that the entire wall is covered and the foot can expand a little onto the shoe. The heels of the shoe should be wide enough to promote spreading of the heels. If the heels are "pinched," they can become contracted, which can lead to lameness.

In general, the angle of the dorsal hoof wall should match the angle at the heels.



It is sometimes a dilemma as to how much heel support to give with the shoe. In some areas, farriers are concerned that if the heels of the shoe are too long, the horse may pull the front shoe off with the hind foot. The hazards of providing inadequate heel support are magnified if the toes are left too long. In these situations, the absence of adequate heel support may promote tenderness in the heels (lameness), and may cause undue strain on the tendons and ligaments along the back of the leg, and may even promote navicular disease (lameness).

In the shod horse, the toe region may grow more hoof than the heel region. For this reason, it is often inappropriate to assess the quality of a farrier's work late in the shoeing cycle.

**Bad things we do to horses' feet:**

1. Neglect: With the domestication of horses, the distances they travel in search of feed and water are reduced. With this comes reduced natural wear of the hoof. If you choose to have a horse, you need to budget between \$50 and \$120 for farrier work every 6 weeks.
2. Poor husbandry: Maintaining horses in a muddy, filthy environment promotes poor hoof health. Ensure that your horse can stand in a dry area for a few hours

per day. There is NO excuse for housing a horse in a stall that is not cleaned daily and bedded with clean straw or shavings.

3. **Soring:** Certain gated horses, especially Tennessee Walking Horses, are sometimes abused. In an effort to accentuate the gait, the feet and legs of these horses are sometimes treated with chemicals or subjected to mechanical trauma (chain, nails, pressure shoeing) that cause pain when the foot hits the ground. In response to this pain, the horse yanks its foot up in an exaggerated gait. Soring of horses is ILLEGAL under the Horse Protection Act. Inspectors are present at many horse shows. If you sore your horse, or allow this to be done by a third party – shame on you.

### ***Selected problems of the hoof***

**Bruises:** Horses may step on a rock or piece of wood, and this may lead to a sole bruise. The ensuing lameness may be mild or severe. If your horse becomes lame, examine the sole for a foreign body. Use your judgment about calling for veterinary attention. The veterinarian will usually watch the horse walk and trot. Then hoof testers will be used to localize the area of pain. The digital pulses will be palpated to detect inflammation in the foot. If the veterinarian determines that a bruise is the most likely cause of a lameness, a bandage may be applied. This may be either a diaper or sheet/roll cotton. Your horse may be administered phenylbutazone (aka Bute, which acts like horse aspirin). Be careful about using Bute without the direction of your veterinarian – this medication may cause gastric and intestinal ulceration and kidney damage.

**Abscesses:** An abscess may form in the hoof, usually between the sensitive and insensitive sole. Horses suffering from a foot abscess may be VERY lame (a fracture may be suspected). The lower limb may be coincidentally swollen. If your horse is extremely lame, your veterinarian should be called. As with the bruise, the area of tenderness will be identified with hoof testers. The abscess may be opened with a hoof knife – prior to this, it may be necessary to sedate the horse or perform a regional nerve block with local anesthetic. After the abscess is opened, your veterinarian may advise you to soak the foot, often in warm water with Epsom salts. The foot may then be bandaged, and the horse administered phenylbutazone. Rarely, the abscess will not drain out the bottom of the foot, but rather will migrate up the hoof wall and drain out at the coronary band. These abscesses may take a few weeks to resolve and can be very frustrating for the horse owner, farrier, and veterinarian.

**Thrush:** As mentioned earlier, thrush is an infection of the frog and sulci, usually secondary to the horse standing in mud or organic matter. Every time you clean out your horse's feet, you should look and smell for the presence of thrush. If you suspect it, you can apply topical medicine such as Koppertox or Thrush-Buster. If your horse develops thrush in the central sulcus of the frog, this area can be gently packed with soft cotton which is then moistened with the thrush medicine.

**Navicular Syndrome** is a very broad term that describes degeneration of the Navicular bone and/or disease of the surrounding support structures. There is no single cause of this syndrome that most likely results from compression of the Navicular bone

and tension on the supporting ligaments. Horses with Navicular syndrome may have mild to severe lameness. They may avoid landing the hoof in the heel region, and may have a short, choppy, stilted stride (often confused with a shoulder-based lameness).

The diagnosis of Navicular syndrome can be very complicated. In general, a methodical lameness examination is indicated. This will include evaluation of the hoof structure and balance, observation at the walk and trot, and response to hoof testers. The response to regional infiltration of a local anesthetic is usually then evaluated. It is most common for the heel region of the hoof to be “blocked out” first with a posterior digital (PD) nerve block. In most cases, the PD block will alleviate the lameness. Some horses will then show a lameness on the *opposite* limb, suggesting that the problem is bilateral. The next step in the diagnosis of the horse’s lameness is to take radiographs. This is most often (and most completely) done with the shoe removed. The standard radiographic series includes 5 views, but may include more. Radiographic signs of Navicular syndrome may include cysts, channels or lollipops in the Navicular bone. It is important to note that there is not a close correlation between severity of lameness and severity of radiographic lesions in Navicular syndrome. It is important to remember that there are MANY other causes of heel-based lameness in the horse.

The veterinarian, possibly in consultation with the farrier, will develop a therapeutic plan for management. This usually involves:

1. Shoeing recommendations: balanced hoof, reduction of toe length, PLENTY of hoof support, +/- change in breakover with a rolled toe, +/- wedge pads to elevate the heels.
2. Exercise: light work is usually encouraged; strenuous exercise during the initial management phase is discouraged.
3. Medications: phenylbutazone is often prescribed. Vasodilators, such as isoxuprine, may be useful.
4. Nutraceuticals: oral or intramuscular joint supplements may be useful.

In some cases, the signs of Navicular syndrome may recur, and your veterinarian may recommend surgical transection of the posterior digital nerve (“nerving”). This procedure is a little controversial, and therefore a discussion with your veterinary to discuss the pros and cons is required.

**Laminitis** literally means “inflammation of the laminae.” In certain pathological situations, the laminae may lose their attachment to hoof wall, allowing the coffin bone to rotate within the hoof capsule, or sink towards the ground (“sinkers”). In general, I like to reserve the term “founder” for horses with severe consequences of laminitis.

Laminitis may occur secondary to a decrease in blood flow to the laminae, perhaps secondary to shunting of the blood between the arterioles and venules (AVA). In severe cases, the laminae between the coffin bone and hoof detach. In most cases, the laminae on the front of the hoof are more severely affected, allowing for tipping of the coffin bone (rotation). In severe cases, the tip of the coffin bone rotates through the bottom of the sole. In other cases, the laminae detach circumferentially, and the coffin bone “sinks” through the bottom of the sole.

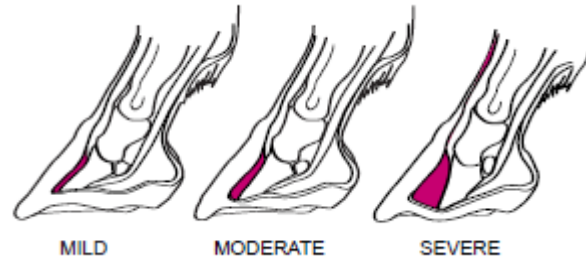


Image from wallerequine.com

Causes of laminitis include grain overload, excess exposure to lush pasture (especially when your horse is not used to it), high fever, toxemia (as from severe colic, or a retained placenta), consumption of cold water in an overheated horse, excessive concussion (road founder). Laminitis is most common in obese horses. Older horses with hyperplasia of the intermediate lobe of the pituitary gland (Cushing's disease) may be at increased risk for laminitis compared to other horses.

Signs of laminitis include mild to severe lameness, reluctance to circle, heat in the foot, increased digital pulses, walking on the heels/avoiding concussion on the toes, "sawhorse" stance. Laminitis is diagnosed through taking a thorough history, doing a thorough physical examination, response to hoof testers and radiographs. Therapy usually includes administration of drugs to minimize pain. Often, phenylbutazone is used, however, other medications such as Banamine and Ketofen may be used. DMSO may be administered intravenously or orally, and acts as an anti-inflammatory agent. An opioid drug, such as butorphanol, may be administered to provide further pain relief. Acepromazine may be administered to increase blood flow to the hoof. Pentoxifylline may be administered to improve blood flow through the small vessels of the foot.

The foot may be supported to limit coffin bone rotation. Frog support, for example by using Lily pads, or sole support with Styrofoam or cast padding, may be used. In some cases, wedge pads may reduce the pull of the deep digital flexor tendon on the coffin bone. The farrier may be instructed to apply a horseshoe "backwards," thereby providing heel support and relieving weight-bearing from the toe. Alternately, an egg bar or heart bar shoe may be used.

In general, exercise should be strictly restricted. The stall should be bedded deeply to encourage the horse to lie down. The prognosis for horses with laminitis is variable. In general, the clinical signs of the horse can be used to guide you as to decisions for continuation of therapy. A horse that cannot or will not rise, is losing weight, developing bed sores, and/or grinding its teeth is a possible candidate for euthanasia. Rotation of the coffin bone through the sole is another indication for euthanasia. In most cases, horses that are "sinkers" are usually euthanized.

References: *Equine Lameness* by Christine King and Richard Mansmann, published by Equine Research, Inc., Grand Prairie, TX.

Please do not reproduce or distribute this text without the permission of Dr. Sally Vivrette. Also, the information in this article represents, in part, the opinions of Dr.

Vivrette. Please consult us for “fine tuning” of this information for your particular situation.